

CASE SPOTLIGHT | Bilateral Type 4 Prostatic Anatomy: The PErFecTED Technique for Atherosclerotic Reflux and Anastomoses

By Zagum Bhatti, MD

PATIENT PRESENTATION

A man in his early 70s presented with severe lower urinary tract symptoms (LUTS) refractory to medical management, primarily complaining of severe nocturia (4-5 times per night), weak stream, and incomplete emptying. His baseline International Prostate Symptom Score (IPSS) was 28, with a quality-of-life score of 5. Preprocedural transrectal ultrasound and MRI revealed a prostate volume of 112 mL with significant median lobe intravesical prostatic protrusion. Digital subtraction angiography was scheduled for prostatic artery embolization.

PROCEDURAL OVERVIEW

Vascular access was achieved via a standard femoral approach. Initial pelvic angiography demonstrated an aortic bifurcation angle and tortuous iliac arteries (Figure 1A). A 5-F Carnevale prostate catheter (CPC 15; Merit Medical Systems, Inc.) was introduced for selection of the internal iliac arteries.

On the left side, there was a type 4 prostatic artery origin, with the proximal segment of the prostatic artery exhibiting significant atherosclerotic disease with high-grade stenosis (Figure 1B and 1C). The 2.5-F Cantata® microcatheter (Cook Medical) was advanced into the more distal prostatic artery, and embolization was initiated with 100–300-µm microspheres.

Intermittent interrogation of the prostatic perfusion during embolization revealed high-resistance reflux into the left internal pudendal artery. Furthermore, high-resolution angiographic mapping revealed a distal anastomosis between the distal prostatic artery and distal internal pudendal artery (Figure 1D).

To achieve therapeutic devascularization of the prostate while preventing catastrophic nontarget embolization to the pudendal territory, execution of the PErFecTED (proximal embolization first, then embolize distal) technique was mandatory. This required advancing the Cantata microcatheter subselectively through the atherosclerotic stenosis and beyond a highly challenging, tight vascular loop distal to the anastomosis. Cantata's shapable tip was configured with a tight distal angle to facilitate advanced tracking. The Cantata crossed the loop

IR-WF1283068-EN-F

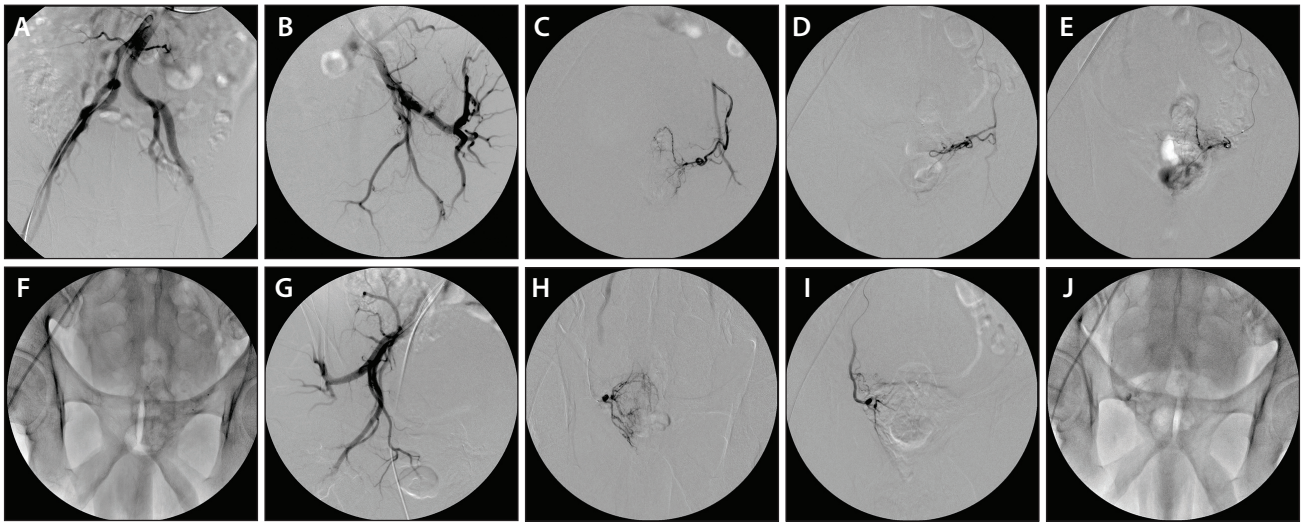

Figure 1. Initial pelvic angiography demonstrating the aortic bifurcation angle and tortuous iliac arteries (A). Left-sided angiography showing a type 4 prostatic artery origin and significant proximal atherosclerotic disease with high-grade stenosis (B, C). Distal anastomosis between the prostatic artery and internal pudendal artery (D). Advancement of the Cantata microcatheter through a tight vascular loop distal to the anastomosis (E). Postembolization fluoroscopy confirming dense, localized embolic staining of the left hemiprostate (F). Right-sided angiography demonstrating a type 4 prostatic artery origin (G). Distal prostatic artery catheterization and angiography during embolization (H, I). Postembolization imaging confirming embolic staining of the right hemiprostate (J).

successfully, maintaining structural integrity and stability (Figure 1E). Embolization was then safely resumed, and postprocedural spot fluoroscopy confirmed dense, localized embolic staining of the left hemiprostate (Figure 1F).

Moving to the right side, a matching type 4 origin was identified (Figure 1G). Upon advancement of the microcatheter into the distal prostatic artery (Figure 1H), embolization was initiated using 100–300-µm beads. To optimize deep particle penetration throughout the large right lobe and actively safeguard the bladder base from nontarget embolic drift (Figure 1I), the PErFecTED technique was performed on this side as well. The microcatheter was advanced into the prostate to complete the lobar devascularization, and excellent embolic staining of the right hemiprostate was confirmed postembolization (Figure 1J).

OUTCOME AND FOLLOW-UP

At the patient's 3-month clinical follow-up, he reported dramatic improvement in LUTS, with his IPSS dropping to 8 and nocturia reducing to one time per night. Follow-up imaging demonstrated excellent volume reduction of the median lobe and an overall prostate volume reduction to 78 mL.

PHYSICIAN DISCUSSION

Type 4 pelvic anatomy paired with severe proximal atherosclerosis is a test of a microcatheter's engineering. In this case, the left proximal prostatic artery stenosis and distal internal pudendal anastomosis complicated matters. The PErFecTED technique was necessary to tackle this safely, and the technique demands a catheter capable of navigating highly tortuous, distal anatomy without kinking or backing out. The microcatheter's torque control and column strength maintain pushability even when navigating past a high-grade atherosclerotic lesion.

On the right side, the catheter's trackability allowed for easy mirroring of the PErFecTED technique, pushing deep into the prostatic tissue to maximize bead penetration while safely isolating and protecting the bladder base. ■